X-RAY STUDY OF A CASE OF POSTURAL COMPENSATION FOR SINGING IN THE UPPER REGISTER

Nicole Scotto Di Carlo
Laboratoire Parole et Langage, E.S.A. 6057
Université de Provence, France

ABSTRACT

This paper presents a case study of a professional soprano with reduced laryngeal mobility caused by substantial calcification of the laryngeal cartilage. Unlike other singers, she lowers her head when singing high notes. A cephalometric analysis revealed a compensatory posture in the upper register consisting of moving the occipital bone backwards and upwards in such a way that the styloid and mastoid processes are also tipped in those directions. This in turn causes the hyoid bone, which is connected to the styloid and mastoid processes by the lesser cornua, to move up and back. Becoming more vertical, it pulls on the superior cornua of the thyroid cartilage to which it is connected by the hyothyroid membrane. This considerably tilts the thyroid cartilage on the cricoid. In reality, this soprano does not lower her head to sing in the upper register; she moves her occipital bone upwards and backwards in order to achieve greater and thus more effective tilting of the thyroid cartilage.

1. INTRODUCTION

A former study on cervical spine abnormalities in professional opera singers [1] demonstrated the existence of specific postures for each of the three registers. For example, the head is raised gradually between the lower and upper registers as the mouth opening becomes increasingly large. Out of the 25 subjects pre-tested for that study, only one, a light coloratura soprano, lowered her head to sing in the upper register, claiming that this made it easier for her to produce high notes (Figure 1). An endoscopic examination indicated hyper-congestion of the rhino-pharyngeal mucosa. An X-ray examination provided evidence of substantial calcification of the larynx, particularly around the cricothyroid joint, suggesting a considerable reduction in laryngeal mobility. In an attempt to determine how this singer is able to tilt her thyroid cartilage properly despite these problems, and to understand how lowering the head might facilitate singing in the upper register, the present study compares a series of X-rays of this soprano during phonation.

2. EXPERIMENTAL PROCEDURE

X-rays of the soprano's head and neck in left/plate position were taken without a cephalostat, first with the singer at rest and then as she produced the French vowels [i], [a], [u], and [ã] in the lower register (on C4) and in the upper register (on C6). A cephalostat is a device generally used to keep the subject's head in the Frankfort Plane[1] so that the bilateral bone structures are superimposed on the resulting x-ray frames. But, although using this technique has little effect on speech, it is a hindrance in singing, where having the head in a fixed position constrains the vocal emission and causes the singer to resort to compensation mechanisms. In order to study this lyrical artist's voice under experimental conditions that would be as much as possible like those encountered in real-life, X-ray bone alignment was sacrificed and the singer was allowed to take on her natural singing position. She was simply told to look straight ahead towards a point located at eye level.

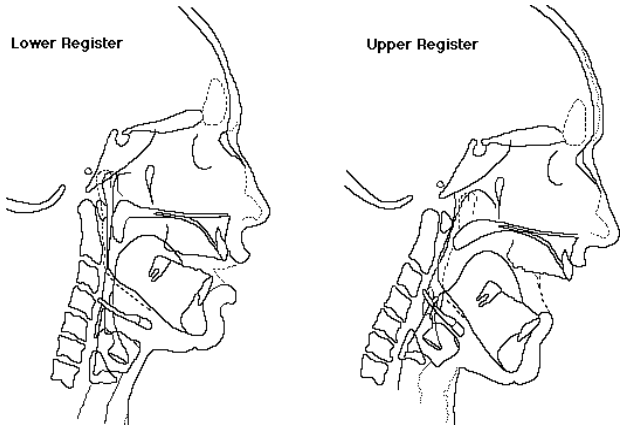

Figure 1. Subject's postures while singing in the lower and upper registers.

3. CEPHALOMETRIC ANALYSIS

Analysis of the X-rays required developing a measurement method that would be suitable for studying the singing voice. The method was derived from cephalometric techniques [2] and used thirteen of the forty cephalometric parameters defined for X-ray studies of phonation [3].

A. Head orientation

Measure of the cephalic inclination angle formed by the Francfort Plane and the Absolute Horizontal drawn through the Sella Point.

B. Degree of cervical curvature

Measure of the odontoidocervical angle at the inflection point in the curvature, formed by the tangent to the highest backmost point of the odontoid and the tangent to the highest backmost point of the seventh cervical vertebra.

C. Anterior-posterior shifts of the cervical spine

Measure of the distance between the lowest point of the sixth cervical vertebra and the perpendicular to the Sella-Nasion Line drawn through the Sella Point.

D. Anterior-posterior shifts of the occiput
Measure of the distance between the Opisthion and the perpendicular to the Sella-Nasion Line drawn through the Sella Point.

E. Vertical shifts of the occiput
Measure of the distance between the Opisthion and the Sella-Nasion Line.

F. Occipital tilt
Measure of the occipital angle formed by the Sella-Nasion Line and the tangent to the lower front part of the occiput.

G. Anterior-posterior shifts of the hyoid bone
Measure of the distance between the Anterior Hyoid Point (lowest and foremost point of the corpus of the hyoid bone) and the perpendicular to the Sella-Nasion Line drawn through the Sella Point.

H. Vertical shifts of the hyoid bone
Measure of the distance between the Anterior Hyoid Point and the Sella-Nasion Line.

I. Hyoid bone tilt
Measure of the hyoid angle formed by the Sella-Nasion Line and the Hyoid Plane (determined by the Anterior and Posterior Hyoid Points).

J. Vertical shifts of the thyroid cartilage
Distance between the highest point of the greater cornu of the thyroid cartilage and the Sella-Nasion Line.

K. Thyroid tilt
Measure of the thyroid angle formed by the Sella-Nasion Line and the line connecting the backmost point of the greater cornu and the backmost point of the lesser cornu of the thyroid cartilage.

L. Buccal opening
Measure of the jaw angle formed by the Palatal Plane (determined by the Anterior and Posterior Nasal Spines) and the Mandibular Plane (determined by the Mental and Gonion Points).

M. Lingual mass orientation
Measure of the lingual angle formed by the Mandibular Plane and the axis of the tongue (determined by the line connecting the middle of the Mandibular Plane and the uppermost point of the tongue) (Figure 2).

4. RESULTS

In professional lyrical artists, singing in the upper register is accompanied by two types of physiological movements: (1) those aimed at achieving maximal tilting of the thyroid cartilage which are common to all singers, and (2) those aimed at tuning the pharyngeal-buccal cavity to the laryngeal sound, which vary with the singer's vocal timbre and intensity [4].

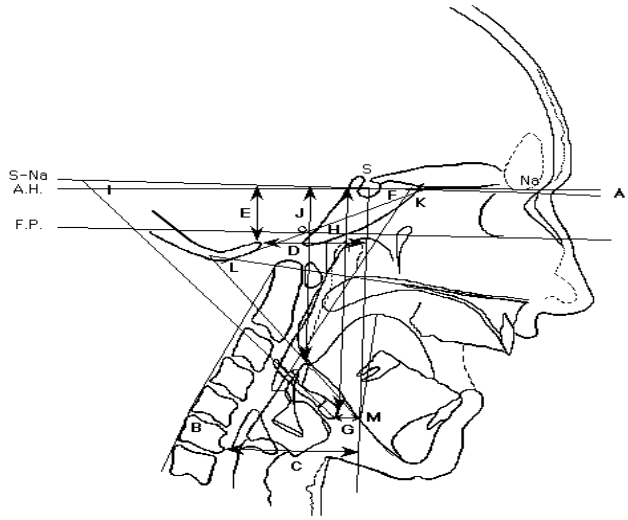

Figure 2. Cephalometric measures used.

The singer studied here is a light coloratura soprano whose voice is soft and clear. When singing in the upper register, she exhibits:

- physiological characteristics common to all singers, i.e., widening of the buccal opening, anteriorization of the lingual mass, posteriorization and verticalization of the hyoid bone, posteriorization and forward tilt of the thyroid cartilage, posterior convexity of the pharyngo-tracheal curvature, dilation of the hypo-pharyngeal space, posteriorization of the pharynx and larynx, posteriorization of the cervical spine, and cervical curvature inversion,
- physiological characteristics specific to her vocal category, i.e., a slight rise of the larynx, lowering and transversal tensing of the velum, lifting of the post-dorsal part of the tongue, a horizontal lip opening, and lateral spreading of the lip corners.

However, the cephalometric analysis pointed out some abnormalities in the subject's head orientation and occipital bone position. While most singers raise their head by 5° when going from the lower to the upper register, this soprano lowers her head by 4 or 5°. Indeed, in the lower register, she raises her head by 6 to 8° whereas in the upper register, the rise is only 2 or 3°. Relatively speaking, then, one can say that she lowers her head between the lower and upper registers (or more precisely, that she raises it less). But in absolute terms, what she actually does is lift her head to sing low notes and move into the horizontal Frankfort position to sing high notes. When going from the lower to the upper register, this singer also shifts the occipital bone backwards, which raises it by 13° to 22°, depending on what vowel is being produced.

Calculation of correlation coefficients between the various parameters brought out a number of other findings. In this soprano, there is a strong correlation between the buccal opening, cervical spine posteriorization, hyoid bone verticalization, and thyroid tilting. In addition, the backward shift of the occiput is highly correlated with hyoid bone verticalization. Finally, the more the head is lowered, the more the thyroid cartilage is tilted (Figure 3).

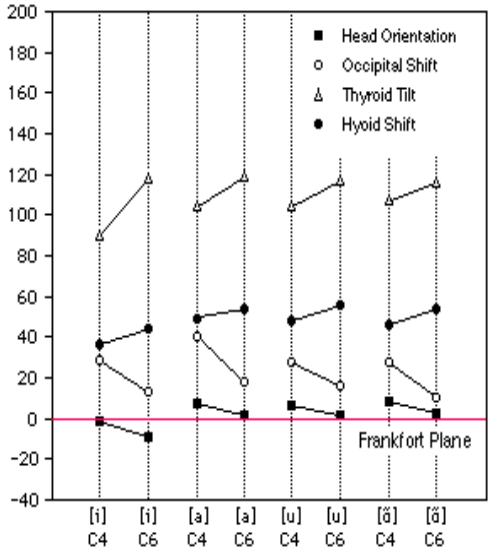

Figure 3. Effect of posture on thyroid tilt.

5. CONCLUSION

Due to extensive calcification of the laryngeal cartilage, which stiffens the cricothyroid joint, the singer studied here is unable to achieve sufficient thyroid tilting for the production of high-quality sounds in the upper register. In order to counteract this lesser mobility, she uses a compensatory posture consisting of moving the occiput backwards and upwards so as to also tilt the styloid and mastoid processes upwards and backwards. This in turn causes the hyoid bone - whose lesser cornua are connected to the styloid process by the stylohyoid muscle and to the mastoidprocess by the digastric posterior belly - to move upwards and backwards. Given that the buccal opening is very large in upper-register singing, the corpus of the hyoid bone is blocked at the bottom by the body of the mandible, while the greater cornua pivot towards the back. As it becomes more vertical, the hyoid bone lifts and brings forward the superior cornua of the thyroid cartilage to which it is connected by the hyothyroid membrane, causing substantial tilting of the thyroid cartilage on the cricoid. It appears as though this soprano is lowering her head to sing high-pitched notes, but in fact, she is raising and posteriorizing her occipital bone in order to achieve maximal tilting of the thyroid cartilage.

This study provides evidence of compensation mechanisms used by a singer with reduced laryngeal mobility which prevents effective thyroid tilting when she is singing in the upper register. It also sheds light on the reasons for a posture which is frequently observed in singers in the early and late stages of their careers, and which until now has appeared totally puzzling.

NOTES

1. The Frankfort Plane is determined by the two Porions (midpoint of the superior part of the external acoustic meatus) and the Sub-0rbital Point. This plane is considered horizontal when the subject standing upright is looking straight ahead at eye level.

REFERENCES

[1]. Scotto Di Carlo, N. 1998. Cervical Column Abnormalities in Professional Opera Singers. *Folia Phoniatrica et Logopaedica,* 50, 4: 212-218.

[2]. Muller, L. 1973. *Céphalométrie et Orthodontie*. Société des Publications Médicales et Dentaires. Paris, 238 pp.

[3]. Scotto Di Carlo, N. 1977. *Application des méthodes céphalométriques à l'étude radiologique de la phonation*. Thesis for admittance to the Cephalometrics Society of America. Philadelphia, 1977. 159 pp.

[4]. Scotto Di Carlo, N. 1991. La voix chantée. *La Recherche*, 22, 235: 1016-1025.

IN MEMORIAM

In memory of Eliane BISER (1943-1999), who supported me throughout those inevitable times of doubt and discouragement that face every researcher, for she believed in the complementarity of Art and Science, in the subtle links that unite artists in their unending quest for Beauty and scientists in their ongoing search for Truth.